

ORIGINAL RESEARCH

# Topical nicotinamide for seborrheic dermatitis: an open randomized study

Gabriella Fabbrocini, Mariateresa Cantelli & Giuseppe Monfrecola

Dipartimento di Medicina Clinica e Chirurgia, Università di Napoli Federico II, Naples, Italy

**Background:** Treatment of seborrheic dermatitis (SD) includes various options with different success and safety limitations. **Objective:** To evaluate the efficacy of topical nicotinamide (NCT) in the treatment of SD. **Methods:** A total of 48 patients with mild to moderate SD of the face were enrolled in the study (36 males and 12 females; age 20–50 years). Patients were randomized into two groups A and B, who were treated once a day with topical administration of NCT 4% cream and with the vehicle without NCT (placebo), respectively. Clinical measures were assessed by erythema, scaling, and infiltration, which were evaluated using a four-point scale 0–3 before starting treatment and after 2, 6, and 12 weeks' therapy. **Results:** In comparison with baseline, a reduction of 75% of the total score was observed in patients treated with NCT, whereas for placebo-treated patients the reduction was of 35% ( $p < 0.05$ ). **Conclusion:** Topical NCT 4% can have a potential for the treatment of SD.

**Key words:** nicotinamide, seborrheic dermatitis, topical treatment

## Introduction

Seborrheic dermatitis (SD) is a common inflammatory dermatosis that may affect infants, adolescents, and adults of all ethnicities (1,2). SD is characterized by the appearance of red, flaking, greasy areas of skin, most commonly on the nasolabial folds, ears, eyebrows, and chest; the scales are greasy. Its pathogenesis is linked to different species of *Malassezia* but also to other unknown factors (3). For its complex pathogenesis, various treatment options are available: antifungal preparations, topical steroids, and keratolytics (4–10).

Nicotinamide (NCT), the amide derivative of vitamin B<sub>3</sub>, alone or in combination with tetracycline antibiotics, has been assessed in numerous clinical studies for the treatment of inflammatory dermatologic condition such as acne vulgaris (11), acne rosacea, and bullous pemphigoid (12). In this open randomized study, we aimed to evaluate the efficacy and safety of NCT in the treatment of SD.

## Materials, patients and methods

### Patients

Forty-eight patients (36 males and 12 females; aged 20–50 years) with mild to moderate SD, attending our outpatient dermatology clinic, were included in the study. All patients provided written

informed consent prior to study enrollment. Coexistent psoriasis, rosacea, and acne vulgaris or any other dermatoses involving the face or other affected area and allergy to medications were criteria for exclusion. Patients who had used any topical and systemic treatments in the previous 1 month were excluded.

### Study design

The study was conducted from October 2010 through February 2012. Patients were randomly divided into two treatment groups. The first group was treated with NCT 4% cream containing sphingolipids as a vehicle, whereas the second received a placebo cream (the same vehicle without NCT). Patients were instructed to treat the affected areas once a day. The area was cleansed and then the cream was applied. No other medications or cosmetics for SD were allowed during the trial. The study was approved by the Institutional Review Board.

### Efficacy assessment

Patients were evaluated by two different investigators (GM and VC). At the initial evaluation, patients were examined and lesions graded numerically for erythema, scaling, and infiltration using a four-point scale from 0 to 3 (0 = none, 1 = mild, 2 = moderate, 3 = severe) as previously used by Koc et al. (13). Patients were examined before treatment and at 2, 6, and 12 weeks, and were asked to report any adverse effects from the medications. All adverse effects such as pruritus, burning sensation, erythema, and others were noted and recorded. Digital photographs were taken with the same camera settings and lighting conditions (Reveal Imager, Canfield Imaging Systems, 253 Passaic Avenue, Fairfield, NJ, USA) before treatment and at 2, 6, and 12 weeks (13).

### Statistical analysis

Nonparametric Wilcoxon test was performed to assess if the independent ordinal samples evaluated satisfy the null hypothesis (H<sub>0</sub>):  $P(X > Y) = 0.5$  or alternative hypothesis (H<sub>1</sub>):  $P(X > Y) = 0.5$ . This test is a nonparametric statistical hypothesis test used when comparing two related samples, matched samples, or repeated measurements on a single sample to assess whether their population mean ranks differ (i.e., it is a paired difference test).

## Results

### Patients

The first group (24 patients) was treated with NCT and the second one (24 patients) with topical placebo. A flowchart of

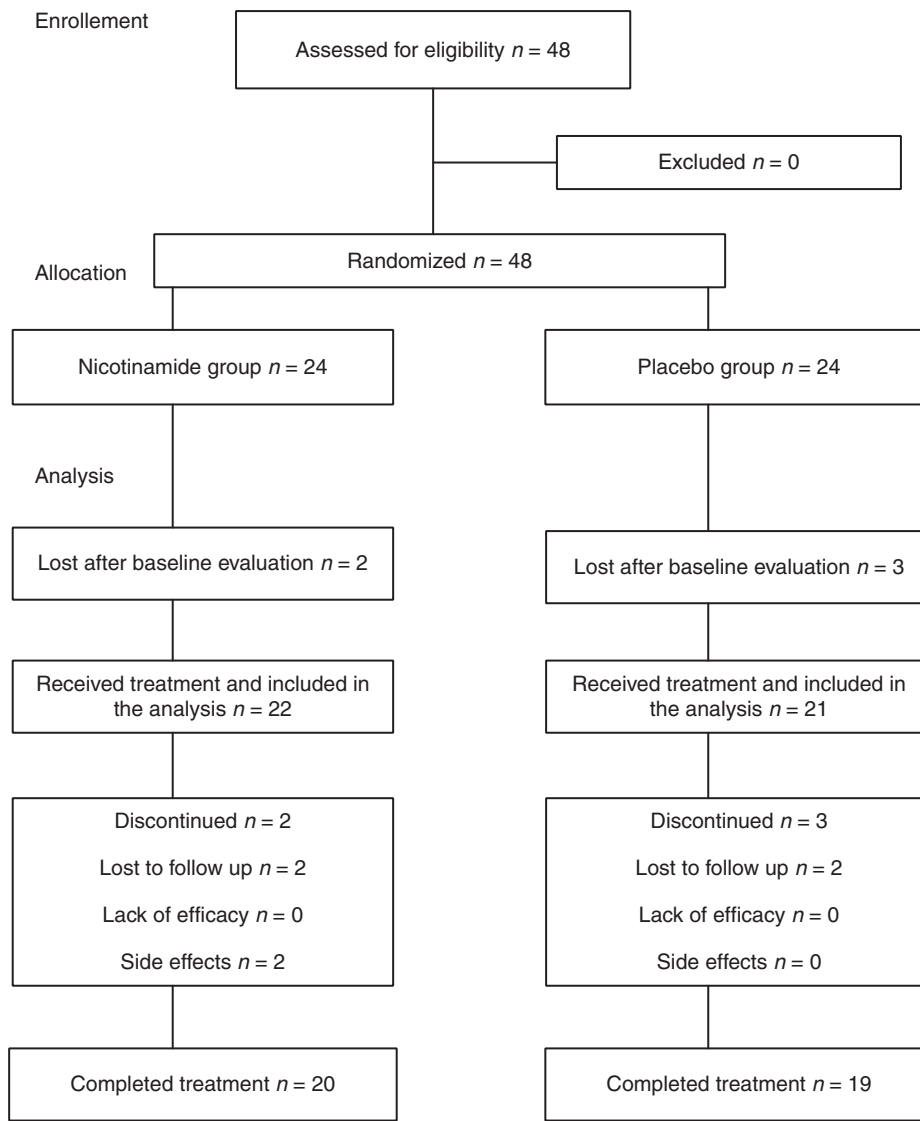
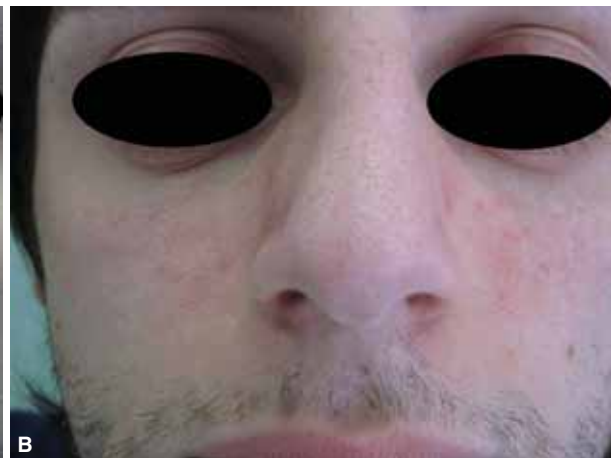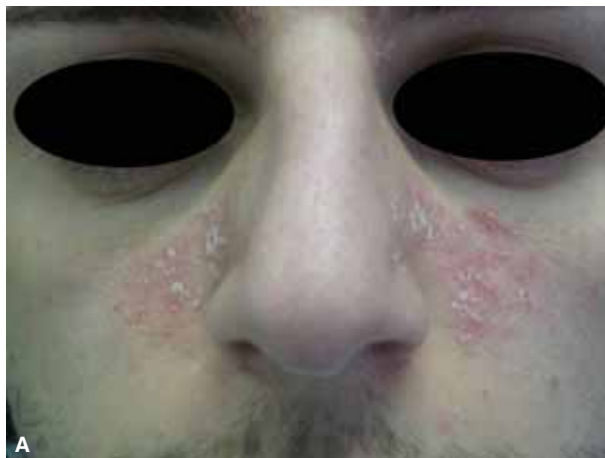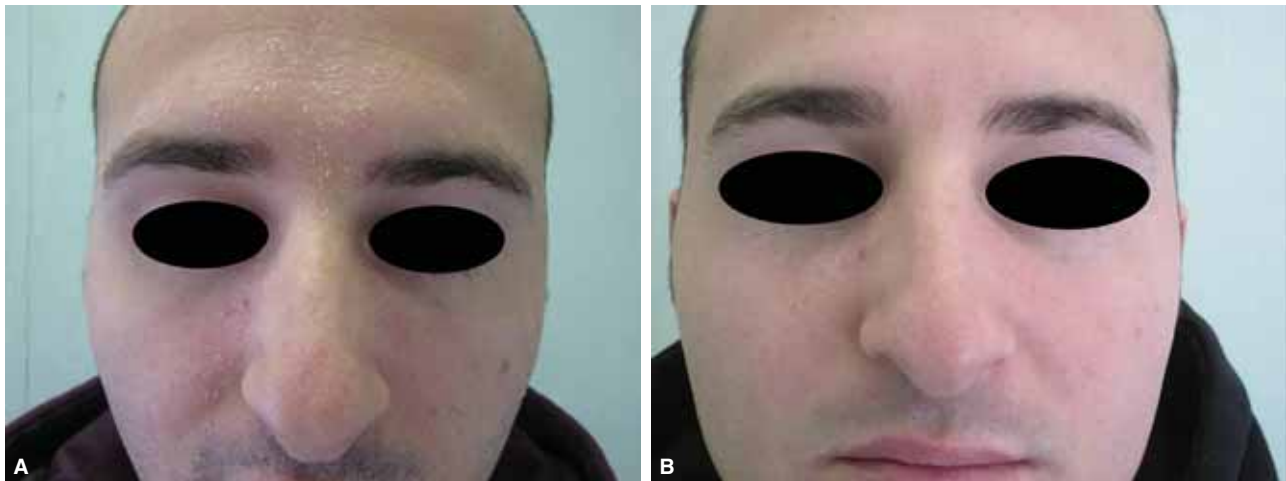


Figure 1. Flowchart of the study.

the study is shown in Figure 1. Twenty patients in the NCT group and 19 patients in the placebo group completed the treatment period. Five patients in both groups left the study (Figure 1). The study focused on the main signs of SD: erythema,

scaling, and infiltration. The total score of the three signs that we evaluated in the treated group was compared with that in the control one. In the group treated with NCT, there was a 75% decrease of the total scores of all signs after treatment with NCT





(Figures 2 and 3). In the control group, there was a 35% decrease of the total score of all signs mainly due to a reduction of scaling because of the presence of glycosphingolipids in placebo cream. Other signs, erythema and infiltration, were not changed during treatment with placebo.

#### Compliance of the therapy

Among patients who concluded the study (81.25%), none referred to avoid the application during the period of therapy. None referred to have side effects that obliged them to suspend the treatment.

#### Treatment efficacy

In comparison with baseline, in the group treated with NCT, there was a statistically significant decrease in erythema, scaling, and infiltration criteria ( $p < 0.05$ ) and there was a higher reduction of signs (75% vs. 35%) in patients treated with NCT (Table I) with respect to patients treated with placebo (Table II). The reduction in scores within each group between

baseline and week 12 was statistically significant according to the Wilcoxon signed-rank test.

#### Side effects

Adverse events were observed in two patients in the NCT group. Adverse events include minimal burning sensation and pruritus. No adverse events were observed in the placebo group.

#### Discussion

Literature shows that NCT can regulate cellular inflammation (14). In fact, NCT blocks proinflammatory cytokines, such as interleukin (IL)-1 $\beta$ , IL-6, IL-8, tissue factor, and tumor necrosis factor (TNF)- $\alpha$  (15–18), as well as transforming growth factor (TGF)- $\beta$ 2 and macrophage chemotactic protein-1 in hepatic cells (19). Ungerstedt et al. demonstrate that NCT has the capacity to downregulate, dose dependently, the cytokine response with a therapeutic potential as a modulator of cytokine effects in inflammatory disease (18). Our results suggest that NCT can modulate

Table I. Data scores from NCT treatment group at time 0 and time 12.

Patients	Before treatment (week 0)				After treatment (week 12)			
	Erythema	Scaling	Infiltration	Total score before treatment	Erythema	Scaling	Infiltration	Total score at the end of the treatment
1	3	2	1	6	2	0	0	2
2	2	2	1	5	0	1	0	1
3	3	2	1	6	1	1	0	2
4	2	2	2	6	0	0	1	1
5	3	3	1	7	1	0	1	2
6	3	2	1	6	1	0	0	1
7	3	3	2	8	1	1	0	2
8	2	1	1	4	0	0	1	1
9	3	2	2	7	1	1	0	2
10	2	2	2	6	0	0	1	1
11	2	2	1	5	1	1	0	2
12	3	2	1	6	1	1	0	2
13	2	2	1	5	0	1	0	1
14	3	2	1	6	1	0	0	1
15	2	2	1	5	1	0	0	1
16	2	2	1	5	0	1	0	1
17	2	3	1	6	1	0	0	1
18	3	2	2	7	1	0	0	1
19	3	1	1	5	1	0	0	1
20	2	2	1	5	1	0	0	1

NCT = nicotinamide.

Table II. Data scores from placebo treatment group at time 0 and time 12.

Patients	Before treatment (week 0)				After treatment (week 12)			
	Erythema	Scaling	Infiltration	Total score before treatment	Erythema	Scaling	Infiltration	Total score at the end of the treatment
1	2	2	1	5	2	1	1	4
2	3	2	1	6	3	1	1	5
3	2	2	1	5	2	3	1	6
4	2	2	1	5	2	1	1	4
5	2	2	1	5	1	2	2	5
6	3	2	1	6	3	1	1	5
7	2	3	1	6	2	3	1	6
8	2	1	1	4	1	1	1	3
9	3	2	2	7	3	1	2	6
10	2	2	2	6	2	1	2	5
11	2	2	1	5	2	2	1	5
12	3	2	1	6	3	1	1	5
13	2	2	1	5	2	2	1	5
14	3	2	1	6	2	2	1	5
15	2	2	1	5	2	1	1	4
16	2	3	1	6	2	3	1	6
17	2	2	2	6	1	2	2	5
18	2	2	1	5	2	1	1	4
19	2	2	1	5	2	2	1	5

the cytokine effects on inflammatory disease. Dougherty et al. support the hypothesis that NCT could inhibit the production of TNF- $\alpha$  and the inflammatory response to induce apoptosis via inhibition of nuclear factor-kappa B (NF- $\kappa$ B) that has a protective role versus apoptotic process and its inhibition can lead to apoptosis (20). NCT seems to inhibit poly(ADP-ribose) polymerase (PARP) (20). The PARP superfamily consists of 17 members, with some of them implicated in the regulation of the immune response. They have been described to influence inflammatory processes through modulating different transcription factors (21,22). PARP-1 in fact interacts with a large number of pro-inflammatory transcription factors and is known to be involved in the pathogenesis of some inflammatory skin diseases like acne (23). The beneficial effects of PARP-1 ablation on inflammatory damage have been shown in multiple disease models such as colitis, arthritis, uveitis, pancreatitis (24) and some inflammatory dermatoses. PARP inhibitors prevented necrotic cell death with a slight increase in apoptotic DNA fragmentation and also reduced cytokine-induced expression of IL-8 and intercellular adhesion molecule 1 (ICAM-1) in human keratinocyte cell line (HaCaT) cells (25). Furthermore, the inhibition of PARP by NCT can explain the therapeutic effect of NCT on SD. Our results highlight these properties. Moreover, Tanno et al. demonstrated that NCT increases ceramides and other intercellular lipids in the stratum corneum (SC), and suggests that NCT may play an important role in the maintenance of the epidermal permeability barrier by regulating SC intercellular lipids synthesis (26). The control of the inflammatory cascade by NCT can explain the significant reduction of SD symptoms showed in our study and can suggest NCT as an optional therapy for SD.

**Declaration of interest:** The authors report no conflicts of interest. The authors alone are responsible for the content and writing of the paper.

## References

- Elewski BE. Safe and effective treatment of seborrheic dermatitis. *Cutis*. 2009;83:333–338.
- Gupta AK, Bluhm R, Cooper EA, et al. Seborrheic dermatitis. *Dermatol Clin*. 2003;21:401–412.
- Bukvić Mokoš Z, Kralj M, Basta-Juzbašić A, Lakoš Jukić I. Seborrheic dermatitis: an update. *Acta Dermatovenerol Croat*. 2012;20:98–104.
- Reichrath J. Antimycotics: why are they effective in the treatment of seborrheic dermatitis? *Dermatology*. 2004;208:174–175.
- Dobrev H, Zissova L. Effect of ketoconazole 2% shampoo on scalp sebum level in patients with seborrheic dermatitis. *Acta Derm Venereol*. 1997;77:132–134.
- Piérard GE, Piérard-Franchimont C, Van Cutsem J, Rurangirwa A, Hoppenbrouwers ML, Schrooten P. Ketoconazole 2% emulsion in the treatment of seborrheic dermatitis. *J Dermatol*. 1991;30:806–809.
- Seckin D, Gurbuz O, Akin O. Metronidazole 0.75% gel vs. ketoconazole 2% cream in the treatment of facial seborrheic dermatitis: a randomized, double-blind study. *J Eur Acad Dermatol Venereol*. 2007;21:345–350.
- Chosidow O, Maurette C, Dupuy P. Randomized, open-labeled, non-inferiority study between ciclopiroxolamine 1% cream and ketoconazole 2% foaming gel in mild to moderate facial seborrheic dermatitis. *Dermatology*. 2003;206:233–240.
- Piérard-Franchimont C, Piérard GE. A double-blind placebo-controlled study of ketoconazole + desonide gel combination in the treatment of facial seborrheic dermatitis. *Dermatology*. 2002;204:344–347.
- Dreno B, Chosidow O, Revuz J, Moysé D; Study Investigator Group. Lithium gluconate 8% vs ketoconazole 2% in the treatment of seborrheic dermatitis: a multicentre, randomized study. *Br J Dermatol*. 2003;148:1230–1236.
- Shalita AR, Smith JG, Parish LC, Sofman MS, Chalker DK. Topical nicotinamide compared with clindamycin gel in the treatment of inflammatory acne vulgaris. *Int J Dermatol*. 1995;34:434–437.
- Fivenson DP, Breneman DL, Rosen GB, Hersh CS, Cardone S, Mutasim D. Nicotinamide and tetracycline therapy of bullous pemphigoid. *Arch Dermatol*. 1994;130:753–758.
- Koc E, Arca E, Kose O, Akar A. An open, randomized, prospective, comparative study of topical pimecrolimus 1% cream and topical ketoconazole 2% cream in the treatment of seborrheic dermatitis. *J Dermatolog Treat*. 2009;20:4–9.
- Maiese K, Chong ZZ, Hou J, Shang YC. The vitamin nicotinamide: translating nutrition into clinical care. *Molecules*. 2009;14:3446–3485.
- Reddy S, Young M, Ginn S. Immunoexpression of interleukin-1beta in pancreatic islets of NOD mice during cyclophosphamide-accelerated diabetes: co-localization in macrophages and endocrine cells and its attenuation with oral nicotinamide. *Histochem J*. 2001;33:317–327.
- Chen CF, Wang D, Hwang CP, Liu HW, Wei J, Lee RP, et al. The protective effect of niacinamide on ischemia-reperfusion-induced liver injury. *J Biomed Sci*. 2001;8:446–452.

17. Moberg L, Olsson A, Berne C, Felldin M, Foss A, Källen R, et al. Nicotinamide inhibits tissue factor expression in isolated human pancreatic islets: implications for clinical islet transplantation. *Transplantation*. 2003;76:1285–1288.
18. Ungerstedt JS, Blömbäck M, Söderström T. Nicotinamide is a potent inhibitor of proinflammatory cytokines. *Clin Exp Immunol*. 2003;131:48–52.
19. Traister A, Breitman I, Bar-Lev E, Zvibel I, Harel A, Halpern Z, et al. Nicotinamide induces apoptosis and reduces collagen I and pro-inflammatory cytokines expression in rat hepatic stellate cells. *Scand J Gastroenterol*. 2005;40:1226–1234.
20. Pero RW, Axelsson B, Siemann D, Chaplin D, Dougherty G. Newly discovered anti-inflammatory properties of the benzamides and nicotinamides. *Mol Cell Biochem*. 1999;193:119–125.
21. Hassa PO, Hottiger MO. The diverse biological roles of mammalian PARPS, a small but powerful family of poly-ADP-ribose polymerases. *Front Biosci*. 2008;13:3046–3082.
22. Yélamos J, Schreiber V, Dantzer F. Toward specific functions of poly(ADP-ribose) polymerase-2. *Trends Mol Med*. 2008;14:169–178.
23. Fabbrocini G, Annunziata MC, D'Arco V, De Vita V, Lodi G, Mauriello MC, et al. Acne scars: pathogenesis, classification and treatment. *Dermatol Res Pract*. 2010;2010:893080.
24. Virág L, Szabó C. The therapeutic potential of poly(ADP-ribose) polymerase inhibitors. *Pharmacol Rev*. 2002;54:375–429.
25. Szabó E, Virág L, Bakondi E, Gyüre L, Haskó G, Bai P, et al. Peroxynitrite production, DNA breakage, and poly(ADP-ribose) polymerase activation in a mouse model of oxazolone-induced contact hypersensitivity. *J Invest Dermatol*. 2001;117:74–80.
26. Tanno O, Ota Y, Kitamura N, Katsube T, Inoue S. Nicotinamide increases biosynthesis of ceramides as well as other stratum corneum lipids to improve the epidermal permeability barrier. *Br J Dermatol*. 2000;143:524–531.